



Type of Manuscript: Case Report

Endoscopic Retrieval of a Dislodged Metallic Dental Fixture in a Patient with Facial Trauma

¹Dr. Rakesh Kumar Jha, Department of Vascular Surgery, INHS Asvini, Mumbai

²Dr. Prasad V. Jayaram, Department of General Surgery, Military Hospital, Bathinda

³Dr. Aabhas Mishra, Department of Gastrointestinal Surgery, INHS Asvini Mumbai

⁴Dr. Nikhil Kumar Mestha, Department of Anaesthesiology, INHS Patanjali, Karwar

Corresponding Author: Dr. Prasad V. Jayaram, Department of General Surgery, Military Hospital, Bathinda Cantonment, Bathinda – 151 001

Email: prasad59@gmail.com

Open Access Article: © 2026, Mr. Prasad V Jayaram, et al. This is an open access journal and article distributed under the terms of the creative common's attribution license (<http://creativecommons.org/licenses/by/4.0>). Which allows others to remix, tweak, and build upon the work non-commercially, as long as appropriate credit is given and the new creations are licensed under the identical terms.

Conflicts of Interest: Nil

Abstract

A gentleman aged about 50 years suffered facial and chest trauma after falling off his bicycle at moderate speed in Western India. The injuries included partially broken upper incisor teeth, full thickness lacerations of the upper lip and blunt trauma of the chest. After initial lavage, the dental debris was removed and the lip lacerations were sutured. A metallic dental retainer was used to stabilise the loose and partially broken incisor tooth. On follow up three days later, the retainer was found to be missing from its original location. A non-contrast chest CT done in view of injuries to chest revealed an impacted metallic foreign body at pyloric antrum – likely a dental implant. In view of the possibility of GI tract perforation by the object and considering the high morbidity associated with open surgery, a decision to attempt endoscopic retrieval was made which proved successful.

Keywords: Endoscopic Foreign Body Retrieval, Ingested Foreign Body, Dental Trauma

Introduction

Injuries associated with falls, including those related to road traffic accidents frequently involve head and neck trauma. These include head injuries with or without intracranial lesions, maxillo-facial fractures and dental trauma. These dental injuries frequently involve chipping or dislodgement of teeth (particularly the incisors and canines), requiring the use of dental implants for management. Here we describe a case where a patient

sustained dental injuries following a fall from his bicycle. Metal wires and a dental implant were used to stabilise the damaged teeth. However, the metal wire was accidentally swallowed by the patient. Since the sharp wire which was lodged at the pylorus could cause a perforation, urgent intervention was indicated. The object was successfully located and safely retrieved endoscopically under topical anaesthesia and the patient's subsequent recovery was uneventful.

Case Report

The patient was riding his bicycle when he fell face-down, sustaining trauma to his face and chest. The impact resulted in multiple full thickness lacerations of the upper lip and partially broken upper incisor teeth with multiple small broken pieces imbedded into the lip wounds. After removal of visible chipped teeth and debris, the lip wounds were sutured in a local primary care clinic and the patient was referred to us for further surgical and dental management. Ortho – Pan Tomogram (OPG) images taken while fixing dental wire for stabilising the incisors revealed multiple left over dental pieces which were retrieved after opening the initially placed sutures. The wound was subsequently closed. The next day, examination revealed absence of a dental implant from its original site.

Subsequently X-rays of the chest and abdomen and CT chest were done which showed the presence of a metallic foreign body at the pyloric antrum. (Figure 1) In the background of the patient's recent trauma and subsequent interventions, it seemed almost certain that the foreign body was an ingested dental wire with sharp ends. In order to avoid potentially fatal complications such as gastro-intestinal perforation, it was decided to retrieve the object endoscopically. Under topical anaesthesia and sedation, the impacted metallic foreign body was located (Figure 2) and retrieved under vision (Figure 3) using a protective hollow oesophageal tube to prevent injury by the sharp ends (Figure 4) of the object while retrieving it. The operation theatre was also kept ready for open laparotomy in case endoscopic retrieval was unsuccessful. The patient recovered well post-procedure. He was initially on a liquid diet initially followed by soft solids, and a fresh dental brace was applied which was kept in place for six weeks and removed thereafter. Presently the

patient is on regular follow-up and has no problems with biting or chewing.

Discussion

Globally, oral-maxillofacial trauma accounts for around 8% of medical emergencies, with road traffic accidents being the main cause of such trauma.¹ A similar trend is reported from India as well. The management of these injuries involves the use of endodontic instruments including brackets and bridges which may be accidentally ingested by the patient. Although 9 out of 10 such foreign bodies pass through the gastrointestinal tract uneventfully,² 10% require endoscopic intervention and 1% need to be retrieved by open surgery.³

Catastrophic complications such as mediastinitis and bowel perforation can occur if the ingested object is sharp and/or metallic.⁴ Therefore the decision of when and how to intervene must be made carefully and in a timely manner.

The 2016 European Society of Gastrointestinal Endoscopy (ESGE) guidelines for removal of upper GI tract foreign bodies recommend CT scan in all patients with suspected perforation or other complication that may require surgery. Whereas they recommend clinical observation without attempting removal in case of asymptomatic patients having ingested blunt and small objects (except batteries and magnets), urgent (within 24 hours) oesophago-gastro-duodenoscopy is recommended for sharp-pointed objects, magnets and batteries. Use of a protective device is recommended while extracting sharp objects in order to avoid oesophago-gastric injury.⁵

These guidelines, together with findings from other papers were reviewed and summarised by Ambe, Weber et al who also stressed the importance of early intervention in cases of sharp ingested objects and the conversion to open surgery if perforation is suspected.⁶

A series of five cases from Singapore showed that the ingested foreign body was only identified on CT (not plain radiograph) in all patients. All five ingested objects were retrieved successfully and in three patients gastric perforations were repaired with endoscopic suturing.⁷

In this series of 97 cases of foreign body ingestion in India, surgical intervention was only required in two patients in whom endoscopic retrieval was unsuccessful.⁸ In the case reported by us, routine dental follow-up revealed absence of metallic implant at its original place which was subsequently localized in lower oesophagus on non-contrast CT of chest. Since the patient didn't have features of mediastinitis or peritonitis, endoscopic approach was considered. Therefore, it appears that attempting early endoscopic retrieval is advisable.

References

1. Palmela Pereira C, Santos R, Santos A, Gonçalves C, Augusto D, Rodrigues A, et al. A systematic review and meta-analysis of oral and maxillofacial trauma. *J Forensic Odontostomatol.* 2022;40(3):2–21.
2. Hou R, Zhou H, Hu K, Ding Y, Yang X, Xu G, et al. Thorough documentation of the accidental aspiration and ingestion of foreign objects during dental procedure is necessary: review and analysis of 617 cases. *Head Face Med* 2016;12(1).
3. Abusamaan M, Giannobile WV, Jhawar P, Gunaratnam NT. Swallowed and aspirated dental prostheses and instruments in clinical dental practice: a report of five cases and a proposed management algorithm. *J Am Dent Assoc* 2014;145(5):45 9–63.
4. Boumarah DN, Binkhamis LS, AlDuhileb M. Foreign body ingestion: Is intervention always a necessity?
5. *Annals of Medicine & Surgery.* 2022;84. doi:10.1016/j.amsu.2022.104944
6. Birk M, Bauerfeind P, Deprez PH, et al. Removal of foreign bodies in the upper gastrointestinal tract in

adults: European Society of Gastrointestinal Endoscopy (ESGE) Clinical Guideline. *Endoscopy* 2016; 48: 489–496.

7. Ambe P, Weber SA, Schauer M, et al. Swallowed foreign bodies in adults. *Dtsch Arztebl Int* 2012; 109: 869–875.
8. Chia DKA, Wijaya R, Wong A, et al. Laparoscopic management of complicated foreign body ingestion: a case series. *Int Surg* 2015; 100: 849–853.
9. Sude NS, Karanam VPK. Endoscopic retrieval of ingested foreign bodies: A single surgeon experience. *Cureus* 2021.

Legend Figures

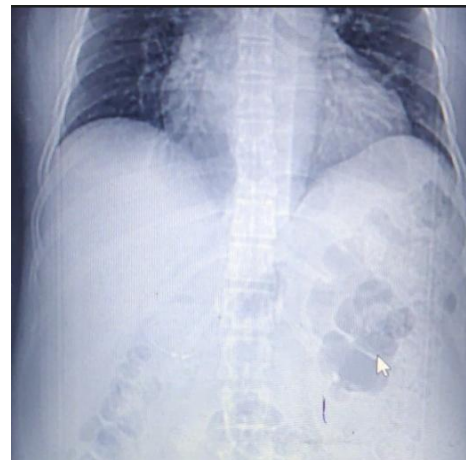

Figure 1: Chest X-ray showing the foreign body

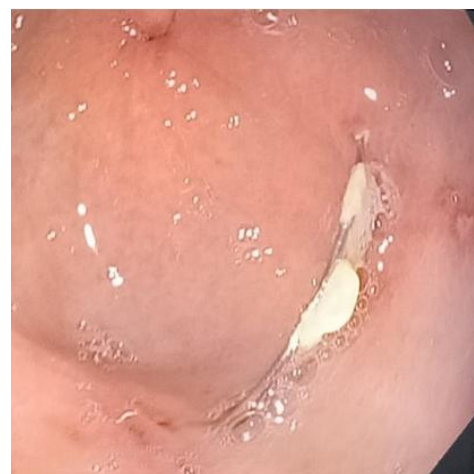


Figure 2: Implant located on endoscopy

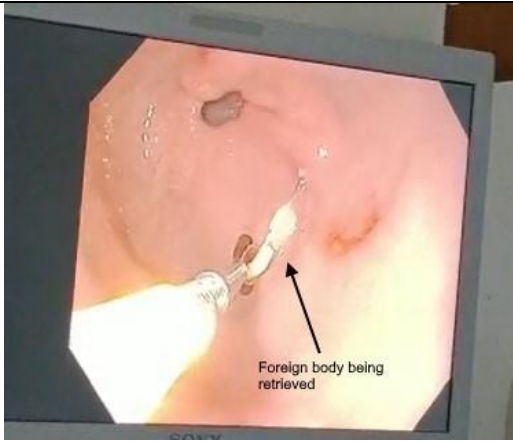


Figure 3: Foreign body being retrieved

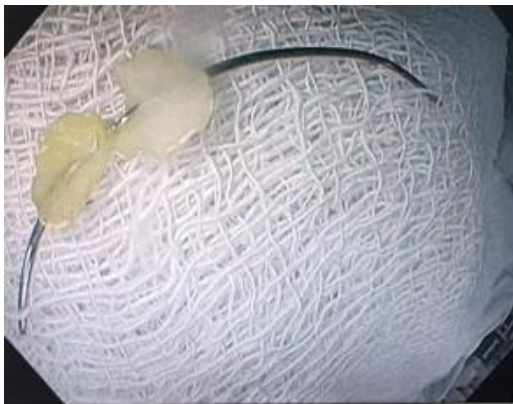


Figure 4: Dislodged implant post recovery